



Case Report

Journal Homepage: <http://crp.tums.ac.ir>

Isolated Pleural Effusion in a Patient With Ankylosing Spondylitis and His Dramatic Response to Prednisolone

Maryam Edalatfard¹ , Besharat Rahimi¹, Hossein Kazemizadeh¹, Behdad Boroofeh¹, Roshan Dinparastisaleh^{2*}

1. Advanced Thoracic Research Center, Tehran University of Medical Sciences, Tehran, Iran.

2. Department of Internal Medicine, School of Medicine, Imam Khomeini Hospital, Urmia University of Medical Sciences, Urmia, Iran.



Citation Edalatfard M, Rahimi B, Kazemizadeh H, Boroofeh B, Dinparastisaleh R. Isolated Pleural Effusion in a Patient With Ankylosing Spondylitis and His Dramatic Response to Prednisolone. *Case Reports in Clinical Practice*. 2018; 3(4):123-127.

Running Title Isolated Pleural Effusion in a Patient With Ankylosing Spondylitis

**Article info:****Received:** 21 October 2018**Revised:** 18 November 2018**Accepted:** 01 December, 2018**Keywords:**

Ankylosing spondylitis (AS); Pleural effusion; Pericardial effusion

ABSTRACT

Ankylosing Spondylitis (AS) is a chronic inflammatory disease of the skeleton manifested by back pain and progressive stiffness of the spine. In AS, the inflammation starts around the entheses (the site of ligament insertion into bone) and typically affects young men with a peak age of onset of 20 to 30 years. Although classically thought as a spinal disease, it can involve other organs such as eyes, lungs, and heart. We present a 49-year-old man with pleural effusion and history of recent pericardial effusion but his fluid studies of pleura and pericardium did not lead us to a clear diagnosis. Then we noticed his thoracic kyphosis, severe restriction of lumbar movements and sacroiliac joint inflammation on MRI which are suggestive of AS. We started prednisolone 50 mg daily for one week and the pleural effusion resolved spontaneously after one week. Then, we tapered prednisolone and the patient remained well off any medication. Isolated pleural and or pericardial effusion may be seen in patients with AS without a simultaneous apical fibrobullous involvement of the lungs and it responds well to corticosteroid.

Introduction

A

nylosing spondylitis (AS) is a chronic inflammatory disease of the skeletal system manifested by back pain and progressive stiffness of the spine. AS is

associated with inflammation around entheses (the site of ligament insertion into bone) and typically affects young men with a peak age of onset of 20 to 30 years. Although classically thought as a spinal disease, AS can involve other organs such as eyes, lungs and heart.

*** Corresponding Author:****Roshan Dinparastisaleh, MD.****Address:** Department of Internal Medicine, School of Medicine, Imam Khomeini Hospital, Urmia University of Medical Sciences, Urmia, Iran.**E-mail:** roshan.dinparast@gmail.com

Case Presentation

A 49-year-old man presented with dyspnea and pleuritic chest pain which had begun several weeks ago and had gradually worsened. The CXR showed bilateral and left-dominant pleural effusion. He was not a smoker, and he did not report hemoptysis, cough, and weight loss. His past medical history revealed that he had two admissions in cardiology hospital in the last 3 months, because of massive pleural and pericardial effusions which underwent diagnostic pericardiocentesis and therapeutic pericardiostomy. Diagnostic studies of pericardial fluid (Gram stain, culture, cytology, AFB stain and culture, ADA) yielded negative results in previous hospitalizations.

On admission, he was afebrile, anxious, moderately dyspneic, with a blood pressure of 135/70 mm Hg, pulse rate of 90 per minute, respiratory rate of 26 per minute, and O₂ saturation of 88% without supplemental oxygen. Breath sounds were diminished on both sides predominantly on the left and showed flatness on percussion. We noticed a kyphosis in thoracic vertebrae on physical examination and spinal movements were severely restricted in all directions. In a more detailed interview, he confirmed that he had chronic back pain for several years. Rest of his physical examinations were normal. His CXR showed bilateral and left-dominant pleural effusion without pericardial effusion and increased cardiothoracic ratio possibly due to kyphosis in thoracic vertebrae (Figures 1 and 2).

The CXR findings were confirmed by chest CT-scan and also cardiomegaly with enlarged pulmonary trunk (39 mm) and elevation of the left hemidiaphragm was noted (Figure 3). Laboratory test results were as follows: hemoglobin 10.5 g/dL, white blood cell-count 11000/mL, with 75% neutrophils, 19% lymphocytes, 7% monocytes and 3% eosinophils. Erythrocyte sedimentation rate was 67 mm/h. Electrolyte levels, urine analysis, renal, liver, and thyroid function tests were all within normal range. No bacterial growth was observed on urine and blood cultures. His tests for antinuclear antibody, anti-double-strand DNA, complement levels and PPD test were negative but rheumatoid factor was weakly positive.

Pleural fluid aspiration revealed a PMN-dominant exudative effusion with an LDH of 209 (serum LDH level was 327), Adenosine-Deaminase (ADA) of 7.9, and total protein of 5.7 g/dl. Pleural fluid tests of smear, Gram stain, culture, and cytology were negative and no acid-fast bacilli were seen. Then, a closed pleural biopsy was performed through pleuroscopy which showed chronic pleuritis with a predominantly lymphocytic inflammation and neither malignant cell infiltration nor granulomatous infiltration of the pleura was observed. A chest-tube was placed for symptom relief and was removed after 24 hours with CXR control.

We obtained lumbosacral X-ray and sacroiliac joint MRI which showed a complete fusion of vertebral column (also called bamboo spine) (Figure 4), and bilateral sacroiliitis. Thus, prednisolone 50 mg daily was begun with a diagnosis of isolated pleural effusion secondary

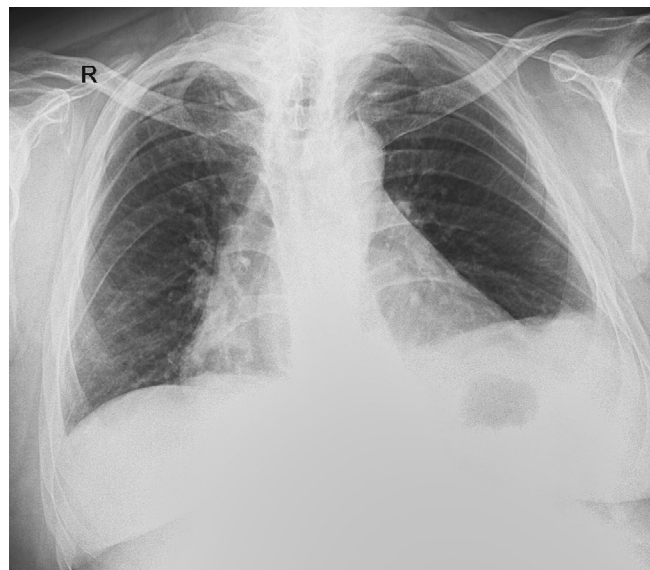


Figure 1. PA CXR showing bilateral pleural effusion

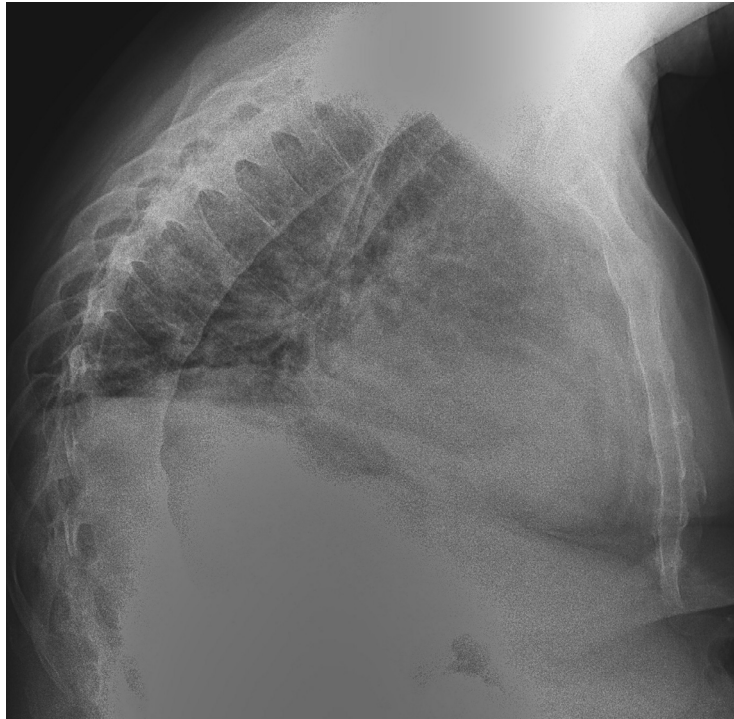


Figure 2. Lateral CXR, showing kyphosis



to Ankylosing Spondylitis. He responded dramatically to corticosteroid and nearly all of his symptoms resolved completely within a few days. Pleural effusion resolved completely on CXR after 1 week. Steroid-dose is gradually tapered to 5 mg/d and the patient remained well off all medications after 3 months.

Discussion

AS is a chronic inflammatory disease of the axial skeleton manifested by back pain and progressive stiffness of the spine. AS is characterized inflammation around the entheses (the site of ligament insertion into bone) and typically affects young men with a peak age of onset of 20 to 30 years. Although it is classically categorized as

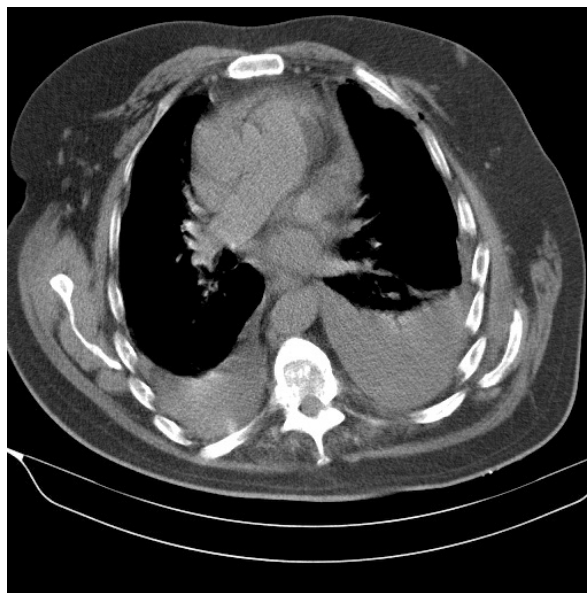


Figure 3. CT-scan showing bilateral pleural effusion



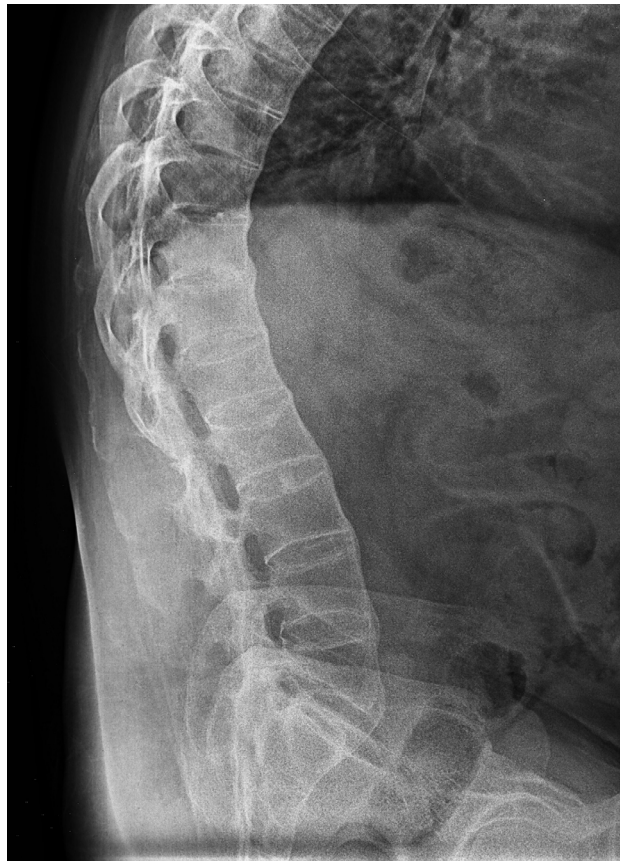

Figure 4. Lateral lumbosacral view showing ankyloses and so-called bamboo spine



a spinal disease, systemic involvement of other organs such as eyes, lungs, and heart can occur.

Pulmonary involvement of AS is a well-known feature of the disease. Apical pleural thickening in association with apical fibroblastic disease is common [1]. Pleural effusion is otherwise rare. The incidence of pleural involvement shows a big variation in the literature, possibly as a result of selection biases. While Spencer et al. reported the pleural effusion incidence as 0% in 200 patients [2] and Rosenow et al. reported 3 out of 2080 patients (0.15%) [1], a much higher prevalence was found by Nagyhegyi et al. with 4 out of 86 patients (5%) [3]. Two of the Rosenow cases had apical fibroblastic disease as well as pleural effusion. One of the cases of Rosenow et al. [1] and two other cases from Kinnear and Shneerson [4] and Erkan et al. [5] had only pleural effusion without apical involvement as in our case. Pleural effusion can be seen on the left side [6] or bilaterally [1].

Although pericardial effusion has been rarely reported in AS patients, to our knowledge, there is only one case reported by Erkan et al. [5] showing pleural and pericardial effusion in AS as manifested in our case. Pleural fluid analysis of the patients with effusion has no discriminative

feature, and is usually exudative and non-hemorrhagic (the exception is a haemothorax case reported by Juric et al. [7]) with normal glucose and pH levels.

Pleural effusion can resolve spontaneously in some AS patients [1]. However, systemic or local anti-inflammatory treatment sometimes is required as recurrence may be a prominent feature of the disease as in our case. Systemic prednisolone (30 mg/d) [4], local administration of steroids (20 mg prednisolone locally to pleural cavity after complete drainage of the effusion) [6], or phenylbutazone (200 mg/d) had been successfully used in the treatment of pleural effusion. We used 50 mg prednisolone per day and then tapered it to 5 mg/d successfully.

In summary, we presented a case of ankylosing spondylitis with a recent pericardial and then pleural effusion without simultaneous apical fibroblastic involvement of the lungs, who responded well to corticosteroid.

Ethical Considerations

Compliance with ethical guidelines

This study was approved by the university human research ethics committee and all procedures performed in studies involving human participants were in accordance with the ethical standards of the institutional and/or national research committee and with the 1964 Helsinki declaration and its later amendments or comparable ethical standards.

Funding

This research did not receive any specific grant from funding agencies in the public, commercial, or not-for-profit sectors.

Conflict of interest

The authors declared no conflict of interest.

References

- [1] Rosenow E, Strimlan CV, Muhm JR, Ferguson RH. Pleuropulmonary manifestations of Ankylosing Spondylitis. *Mayo Clinic Proceedings*. 1977; 52(10):641-9. [PMID]
- [2] Spencer DG, Park WM, Dick HM, Papazoglou SN, Buchanan WW. Radiological manifestations in 200 patients with Ankylosing Spondylitis: Correlation with clinical features and HLA B27. *The Journal of Rheumatology*. 1979; 6(3):305-15. [PMID]
- [3] Nagyhegyi G, Nadas I, Banyai F, Luzsa G, Geher P, Molnar J, et al. Cardiac and cardiopulmonary disorders in patients with Ankylosing Spondylitis and rheumatoid arthritis. *Clinical and Experimental Rheumatology*. 1988; 6(1):17-26. [PMID]
- [4] Kinnear WJ, Shneerson JM. Acute pleural effusions in inactive Ankylosing Spondylitis. *Thorax*. 1985; 40(2):150-1. [DOI:10.1136/thx.40.2.150] [PMID] [PMCID]
- [5] Erkan L, Uzun O, Findik S, Atici AG, Ozkaya S. Isolated pleural and pericardial effusion in a patient with Ankylosing Spondylitis. *Respiratory Medicine*. 2007; 101(2):356-8. [DOI:10.1016/j.rmed.2006.04.028] [PMID]
- [6] Tanaka H, Itoh E, Shibusa T, Chiba H, Hirasawa M, Abe S. Pleural effusion in Ankylosing Spondylitis: Successful treatment with intra-pleural steroid administration. *Respiratory Medicine*. 1995; 89(7):509-11. [DOI:10.1016/0954-6111(95)90129-9]
- [7] Juric G, Coumas JM, Giansiracusa DF, Irwin RS. Hemothorax- An unusual presentation of spinal fracture in Ankylosing Spondylitis. *The Journal of Rheumatology*. 1990; 17(2):263-6. [PMID]