

Idiopathic Central Sleep Apnea: A Case Report

Besharat Rahimi¹, Hossein Kazemizade¹, Maryam Edalatifard^{1*}

¹ Advanced Thoracic Research Center, Tehran University of Medical Sciences, Tehran, Iran

Received: 06 Feb. 2018 Accepted: 26 Mar. 2018

Abstract

Background and Objective: Central sleep apnea (CSA) is defined as cessation of breathing in the absence of ventilatory drive for at least 10 seconds. Idiopathic central sleep apnea (ICSA) is a rare disorder with unclear etiology, and diagnosis is made upon exclusion of other causes. Many of the patients with ICSA do not receive appropriate treatment.

Case Report: Here, we report a 38-year-old man with history of daily hypersomnolence and decreased concentration since two years before referring to our center. After comprehensive medical approach for CSA, he was diagnosed as ICSA. The patient did not respond and did not tolerate continuous positive airway pressure (CPAP). Zolpidem was prescribed for the patient, and he had dramatic improvement of symptoms.

Conclusion: ICSA is a rare sleep breathing disorder presenting with CSA, and may be misdiagnosed with other causes of CSA in the cases of non-appropriate medical evaluation. However, there is no definite treatment.

© 2018 Tehran University of Medical Sciences. All rights reserved.

Keywords: Continuous positive airway pressure; Central sleep apnea; Polysomnography

Citation: Rahimi B, Kazemizade H, Edalatifard M. **Idiopathic Central Sleep Apnea: A Case Report.** *J Sleep Sci* 2018; 3(1-2): 41-4.

Introduction

Idiopathic central sleep apnea (ICSA) is a central sleep apnea (CSA) characterized by periodic events of apnea and hypopnea resulting from decreased neural input to the respiratory motor neurons (1). Prevalence of ICSA in general population is not known; however higher prevalence is reported in older patients (2).

Two large epidemiologic studies reported a prevalence of 0.4% in men (2) and essentially 0% in women (3).

Patients with ICSA hyperventilate with low partial pressure of carbon dioxide (pCO₂). The tendency to hyperventilation is related to increased responsiveness of the peripheral and central chemoreceptors that increase loop gain and lead to respiratory instability (4). ICSA has no proven standard treatment (5). Continuous positive airway pressure (CPAP) is effective in some of the patients, but not all. Some pharmacological agents also are used in treatment of ICSA.

Zolpidem has a favorable safety profile in range of clinical situation, and is used in treatment of ICSA (6).

Case Report

A 38-year-old man presented with history of daytime hypersomnolence and decreased concentration since two years before. He reported two car accidents during past two years. He denied snoring and night choking. His weight was 107 kg, and height was 178 cm [body mass index (BMI): 33.8 kg/m²].

He was not smoker or alcohol user. He denied taking opium, other drugs, and medications. He had not history of cardiovascular and respiratory problems. He had not recent travel to high altitude.

Blood pressure was 110/70 mmHg. Respiratory rate was 13 per minute, with a regular pattern. Ear, nose, and throat (ENT), chest, and heart examination revealed no abnormal finding. Diagnostic sleep study was performed as polysomnography (PSG) with 37 channels with video monitoring (SOMNOscreen™ Plus, SOMNOMedics America Inc., Coral Gables, FL, USA).

* **Corresponding author:** M. Edalatifard, Advanced Thoracic Research Center, Tehran University of Medical Sciences, Tehran, Iran
Tel: +98 21 61192664, Fax: +98 21 66581594
Email: maryam_edalatifard@yahoo.com

Studied electrophysiologic sleep parameters included frontal, central, and occipital electrocephalogram. Airflow was recorded by nasal pressure and thermistor sensors. The arterial oxygen saturation (SpO₂) was measured by oximeter. Analysis of PSG findings indicated CSA with low arousals (Figure 1 and Table 1).

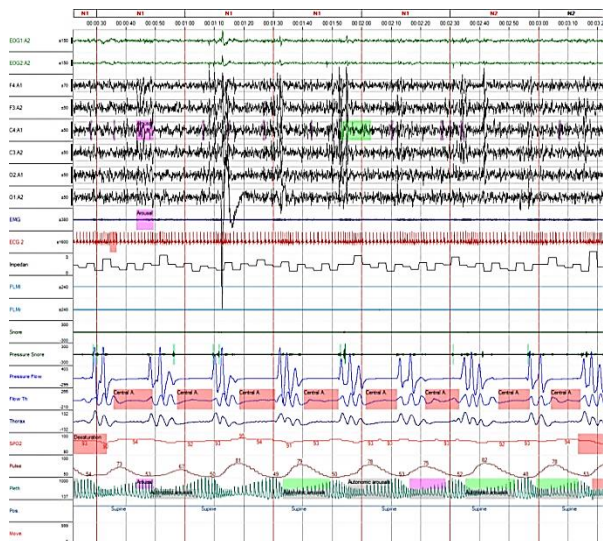


Figure 1. Central sleep apnea in 300 seconds' window of polysomnography

The patient had normal cardiac rhythm on electrocardiography (ECG), and his ejection fraction (EF) was 55% in echocardiography.

Table 1. Polysomnographic characteristics of the patient

| Polysomnographic characteristics | Value |
|---|-------|
| Obstructive apnea (/hour) | 2.9 |
| Obstructive hypopnea (/hour) | 8.6 |
| Central apnea (/hour) | 36.3 |
| Oxygen desaturation index (ODI) (/hour) | 12.8 |
| Respiratory disturbance index (RDI) (/hour) | 47.8 |
| Sleep efficiency (%) | 93 |
| Arousal index (/hour) | 13.1 |
| Minimal SpO ₂ (%) | 86 |
| Baseline SpO ₂ (%) | 94 |
| SpO ₂ time < 90% (%) | 2.1 |

SpO₂: Arterial oxygen saturation

For understanding etiology of CSA, evaluation of neurologic and heart disorders and arterial blood gas (ABG) test was performed. Brain magnetic resonance imaging (MRI) was done, and is depicted in figures 2 and 3. Neurologic examination was completely normal.

ABG parameters of the patient were as pH: 7.36, partial pressure of carbon dioxide (PaCO₂): 39.6 mmHg, HCO₃⁻: 23 mmol/l, and PaO₂: 82 mmHg. Patient's laboratory data also was in nor-

mal range [fasting blood sugar (FBS): 102 mg/dl), thyroid stimulating hormone (TSH): 2.1 mIU/l, creatinine: 0.8 mg/dl).

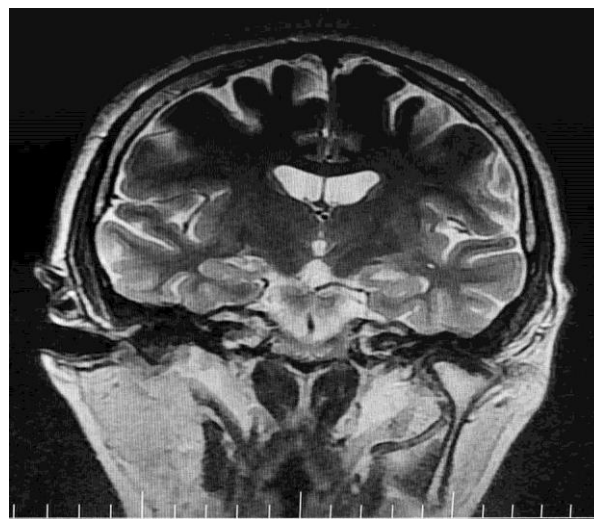


Figure 2. Coronal view of patient's brain magnetic resonance imaging (MRI)

By excluding etiologies of CSA, ICSA was considered for patient's diagnosis.

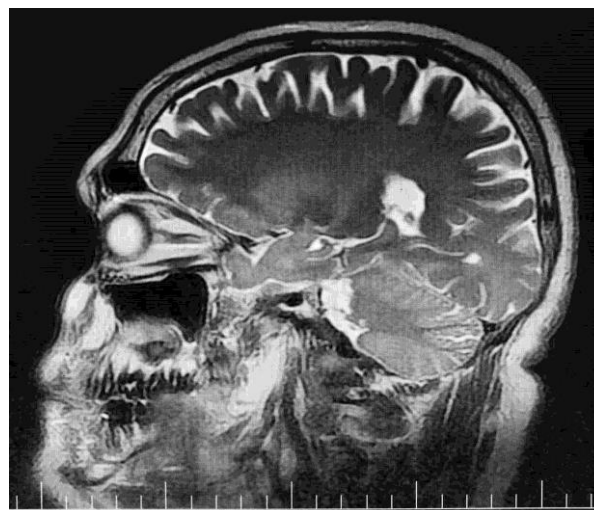


Figure 3. Sagittal view of patient's brain magnetic resonance imaging (MRI)

Manual in laboratory CPAP titration was also performed. But, the patient did not tolerate CPAP on the titration study, and did not respond well. Zolpidem was prescribed for him, and his symptoms dramatically decreased.

Discussion

CSA is described as a transient cessation of central drive for respiration to involved muscles in

the process of respiration resulting in absence of nasal airflow (7). According to the criteria of International Classification of Sleep Disorders 3 (ICSD-3) for diagnosis of CSA, symptoms of sleepiness, snoring, witnessed apnea or difficulty in initiating or maintaining sleep must be met. Furthermore, other criteria like five and more central apnea or hypopneas per hour or central events of more than 50% of the total number of apnea and hypopneas in the absence of nocturnal hypoventilation and medication use must be met, too (8).

CSA is most often due to fall in arterial PaCO₂ below the threshold required to stimulate breathing. Full overnight PSG with diagnostic tools capable of detecting respiratory effort and air flow limitation is required for diagnosis of CSA (9). CSA can develop owing to various causes (10). ICOSA is a diagnosis of exclusion as other causes of central sleep apnea noted below are excluded. The causes of CSA that must be ruled out after ICOSA diagnosis include Cheyne-Stokes breathing, high-altitude CSA, CSA due to opium and drugs, and neurologic disorders (8).

In our case, neurologic related causes (trauma, brain damage due to accident, and posterior fossa space-occupying lesions) were excluded based on neurologic examination and normal brain MRI. He strongly denied opium intake, and his breathing was not ataxic as seen in subjects with chronic opiate use (11). Cheyne-Stokes breathing was not observed in PSG and clinical examination, and echocardiography ruled out cardiovascular etiologies. He lived in Tehran, Iran, and Tehran altitude from sea level is 1189 m; so, high altitude periodic breathing was ruled out, because high altitude periodic breathing is seen beyond 4000 m from sea level. Hence, the diagnosis of ICOSA was made for the patient. ICOSA is thought to develop in the setting of hyperventilation with hypocapnia (12), and different approaches have been described to treat CSA depending upon its subtypes (13).

CPAP is considered to be effective in ICOSA by improving oxygenation (13). Hence, we planned to titrate our patient with CPAP but patient did not respond well, and did not tolerate at all. A study demonstrated that zolpidem can improve ICOSA by maintaining the sleep, and decreasing arousals (14). Mentioned treatments are used for small sample of patients, thus much larger randomized trial studies are required on this issue. Zolpidem was prescribed for our patient. In follow-up visits, patient's symptoms dramatically decreased.

Conclusion

CSA is characterized by cessation of airflow in the absence of respiratory effort during PSG. ICOSA is a rare sleep breathing disorder presenting with CSA, and may be misdiagnosed with other causes of CSA in the case of non-appropriate medical evaluation. However, there is no definite treatment.

Conflict of Interests

Authors have no conflict of interests.

Acknowledgments

The authors wish to thank Mr. Naghipour and the staff of Imam Khomeini Sleep Lab Center, Tehran, Iran.

References

- Bradley TD, Phillipson EA. Central sleep apnea. *Clin Chest Med* 1992; 13: 493-505.
- Bixler EO, Vgontzas AN, Ten Have T, et al. Effects of age on sleep apnea in men: I. Prevalence and severity. *Am J Respir Crit Care Med* 1998; 157: 144-8.
- Bixler EO, Vgontzas AN, Lin HM, et al. Prevalence of sleep-disordered breathing in women: Effects of gender. *Am J Respir Crit Care Med* 2001; 163: 608-13.
- Xie A, Wong B, Phillipson EA, et al. Interaction of hyperventilation and arousal in the pathogenesis of idiopathic central sleep apnea. *Am J Respir Crit Care Med* 1994; 150: 489-95.
- Bradley TD, McNicholas WT, Rutherford R, et al. Clinical and physiologic heterogeneity of the central sleep apnea syndrome. *Am Rev Respir Dis* 1986; 134: 217-21.
- Quera-Salva MA, McCann C, Boudet J, et al. Effects of zolpidem on sleep architecture, night time ventilation, daytime vigilance and performance in heavy snorers. *Br J Clin Pharmacol* 1994; 37: 539-43.
- Zucconi M, Ferri R. B. Assessment of sleep disorders and diagnostic. In: Bassetti C, Dogas Z, Peigneux P, Editors. *Sleep medicine textbook*. Regensburg, Germany: European Sleep Research Society; 2014. p. 98-9.
- Berry RB, Brooks R, Gamaldo CE, et al. The AASM manual for the scoring of sleep and associated events: Rules, terminology and technical specifications. Darien, IL: American Academy of Sleep Medicine; 2014.
- Ryan CM, Bradley TD. Central sleep apnea. In: Broaddus VC, Mason RC, Ernst JD, Editors. *Murray & Nadel's textbook of respiratory medicine e-book*. Philadelphia, PA: Elsevier Health Sciences; 2015. p. 1569-82.
- Malhotra A, Owens RL. What is central sleep apnea? *Respir Care* 2010; 55: 1168-78.

11. Walker JM, Farney RJ, Rhondeau SM, et al. Chronic opioid use is a risk factor for the development of central sleep apnea and ataxic breathing. *J Clin Sleep Med* 2007; 3: 455-61.

12. Szollosi I, Jones M, Morrell MJ, et al. Effect of CO₂ inhalation on central sleep apnea and arousals from sleep. *Respiration* 2004; 71: 493-8.

13. Eckert DJ, Jordan AS, Merchia P, et al. Central sleep apnea: Pathophysiology and treatment. *Chest* 2007; 131: 595-607.

14. Quadri S, Drake C, Hudgel DW. Improvement of idiopathic central sleep apnea with zolpidem. *J Clin Sleep Med* 2009; 5: 122-9.