

Hughes Stovin Syndrome



Besharat Rahimi , Maryam Edalatifard 

Thoracic Research Center, Tehran University of Medical Sciences, Tehran, Iran.



Citation Rahimi B, Edalatifard M. Hughes Stovin Syndrome. Case Reports in Clinical Practice. 2018; 3(3):94-95.

Running Title Hughes Stovin Syndrome.



Keywords:

Hughes-Stovin syndrome; Pulmonary aneurysm; Deep venous thrombosis

Article info:

Received: 18 July 2018

Revised: 13 August 2018

Accepted: 3 September 2018

Introduction

Hughes-Stovin Syndrome (HSS) is a auto immune disorder, that presents with Deep Venous Thrombosis (DVT) and pulmonary and or bronchial aneurysms.

Case Presentation

49-year-old man was referred to outpatient clinic with dyspnea that started 4 year ago, but his symptoms got worse in the previous year [functional class II of New York Heart Association (NYHA)].

He reported no chest pain, hemoptysis or sudden onset of dyspnea. He complained of intermittent fever since 3 months ago. His medical history revealed that he was a heavy smoker (40 packs/year) and had a deep vein thrombosis in left leg two months ago. He received warfarin 5 mg/d and his INR (International Normalized Ratio) was in ideal range.

His vital signs were stable except oxygen saturation of 89% on room air and decreased breath sounds in both lungs. Another exam was intact. There was obstructive pattern in spirometry. His chest computed tomography scan showed large central pulmonary arteries (**Figure 1**) with multiple aneurysmal dilatation of

* Corresponding Author:

Maryam Edalatifard, PhD.

Address: Thoracic Research Center, Tehran University of Medical Sciences, Tehran, Iran.

E-mail: m-edalatifard@sina.tums.ac.ir

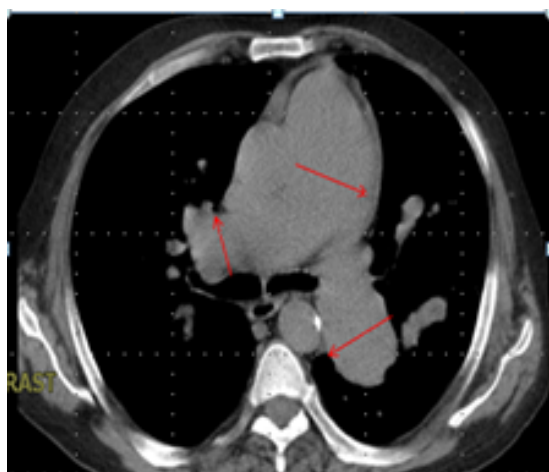

Figure 1. Large central pulmonary arteries

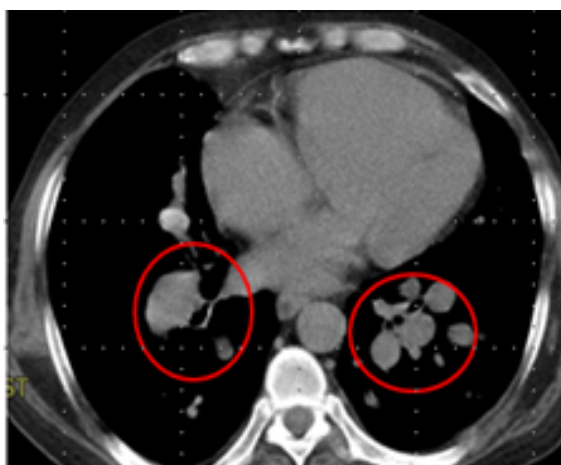


Figure 2. Multiple aneurysmal dilatation of right and left pulmonary arteries

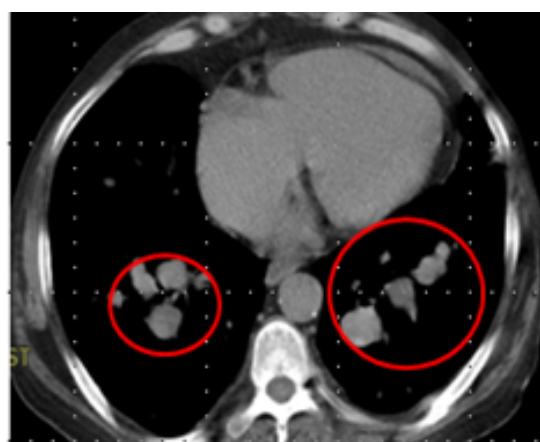


Figure 3. Multiple aneurysmal dilatation of right and left pulmonary arteries

right and left pulmonary arteries (Figures 2 and 3) The final diagnosis was Hughes-Stovin syndrome.

Discussion

Hughes-Stovin Syndrome (HSS) is a rare auto immune disorder, characterized by Deep Venous Thrombosis (DVT) and pulmonary and or bronchial aneurysms. The pathogenesis is not clear, but it is assumed to be a consequence of angiodysplasia and vasculitis similar to those in Behcet's Disease (BD) [1]. If a patient presents with this set of findings (aneurysms and thrombosis) and the clinician is able to rule out other causes, then the patient either has HSS or BD [2]. The management of HSS is medical (steroid and cytotoxic agent) and not surgical.

Ethical Considerations

Compliance with ethical guidelines

All ethical principles were considered in this article. The participant was informed about the purpose of the research and its implementation stages.

Funding

This research did not receive any specific grant from funding agencies in the public, commercial, or not-for-profit sectors.

Conflict of interest

The authors declare no conflict of interest.

References

- [1] Tekave Trikanjec J, Tudoric N, Vukelic- Markovic M, Vrbica Z. Hughes - Stovin Syndrome: A case report. *European Respiratory Journal*. 2015; 46:PA248. [DOI:10.1183/13993003.congress-2015.PA2481]
- [2] Khalid U, Saleem T. Hughes-Stovin Syndrome. *Orphanet Journal of Rare Diseases*. 2011; 6:15. [DOI:10.1186/1750-1172-6-15] [PMCID] [PMCID]